

Short Communication

Thyroid Nodules

Rajiv Datta*

Department of Surgery, Mount Sinai South Nassau, One Healthy Way, Oceanside, NY, 11572, USA

Over the last few years, the prevalence of thyroid nodules has increased. There are multiple reasons: true increase in incidence and increase in investigations with better technology. Finding a nodule in the thyroid does lead to a flurry of investigations. Chiefly among them is ultrasound, which is followed by a fine needle biopsy. Once a diagnosis of malignancy is made, treatment is based on the type and size of the cancer, patient characteristics, and the practitioner who sees the patient. Even though there are multiple guidelines by various societies [1], such as the National comprehensive cancer network (NCCN), American Association of clinical endocrinology (AAACE), American Thyroid Association (ATA), American College of Radiology (ACR), etc. there is still an overzealous pattern of investigations and treatment. Despite the recommendation not to biopsy sub-centimeter nodules, it is almost routine in the community for the nodules to be biopsied. Again, when it comes to treatment, extreme treatments are done such as total thyroidectomy for sub-centimeter papillary thyroid cancers. Various societies have done their best to disseminate the guidelines to radiologists, endocrinologists, and surgeons. However, due to the ubiquitous nature of the diagnosis of thyroid nodules, these guidelines tend to get ignored. Most radiologists do not follow the guidelines of thyroid imaging, reporting, and data system (TI-RADS) [2], which leads to misinterpretation of the risk factors. Ultrasound-guided FNA is performed. The reporting structure is standardized, and almost every pathology lab reports the Bethesda criteria [3]. However, when it comes to interpretation, once again the guidelines are not followed, including radical surgery such as Total Thyroidectomy, which may not be necessary. After surgery, over-treatment is seen using radioactive iodine.

Since the diagnosis of thyroid nodules has increased over the last few years, it becomes imperative that standardization across the board is done with the management which includes ultrasound reporting, surgical treatment of the nodules, and postoperative follow-up.

Even though the various societies have done a great job in putting on the guidelines, it is still not followed in the community.

More Information

*Address for Correspondence: Rajiv Datta, Department of Surgery, Mount Sinai South Nassau, One Healthy Way, Oceanside, NY, 11572, USA, Email: rdatta@snch.org; rajiv.datta@snch.org

Submitted: September 15, 2022

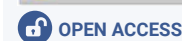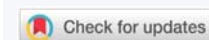
Approved: September 21, 2022

Published: September 22, 2022

How to cite this article: Datta R. Thyroid Nodules. *Ann Clin Endocrinol Metabol.* 2022; 6: 010-010.

DOI: 10.29328/journal.acem.1001025

Copyright License: © 2022 Datta R. This is an open access article distributed under the Creative Commons Attribution License, which permits unrestricted use, distribution, and reproduction in any medium, provided the original work is properly cited.



It should be made mandatory that a) sonographic evaluation of the thyroid should be read in a standardized fashion by all radiologists, b) cytologist report using the Bethesda system and utilization of molecular analysis when required and c) Appropriate management by the surgeons based on the guidelines. Doing this will reduce the number of unnecessary surgical procedures and the anxiety of the patients.

References

- Haugen BR, Alexander EK, Bible KC, Doherty GM, Mandel SJ, Nikiforov YE, Pacini F, Randolph GW, Sawka AM, Schlumberger M, Schuff KG, Sherman SI, Sosa JA, Steward DL, Tuttle RM, Wartofsky L. 2015 American Thyroid Association Management Guidelines for Adult Patients with Thyroid Nodules and Differentiated Thyroid Cancer: The American Thyroid Association Guidelines Task Force on Thyroid Nodules and Differentiated Thyroid Cancer. *Thyroid.* 2016 Jan;26(1):1-133. doi: 10.1089/thy.2015.0020. PMID: 26462967; PMCID: PMC4739132.
- Grant EG, Tessler FN, Hoang JK, Langer JE, Beland MD, Berland LL, Cronan JJ, Desser TS, Frates MC, Hamper UM, Middleton WD, Reading CC, Scoutt LM, Stavros AT, Teefey SA. Thyroid Ultrasound Reporting Lexicon: White Paper of the ACR Thyroid Imaging, Reporting and Data System (TIRADS) Committee. *J Am Coll Radiol.* 2015 Dec;12(12 Pt A):1272-9. doi: 10.1016/j.jacr.2015.07.011. Epub 2015 Sep 26. PMID: 26419308.
- Cibas ES, Ali SZ. The 2017 Bethesda System for Reporting Thyroid Cytopathology. *Thyroid.* 2017 Nov;27(11):1341-1346. doi: 10.1089/thy.2017.0500. PMID: 29091573.